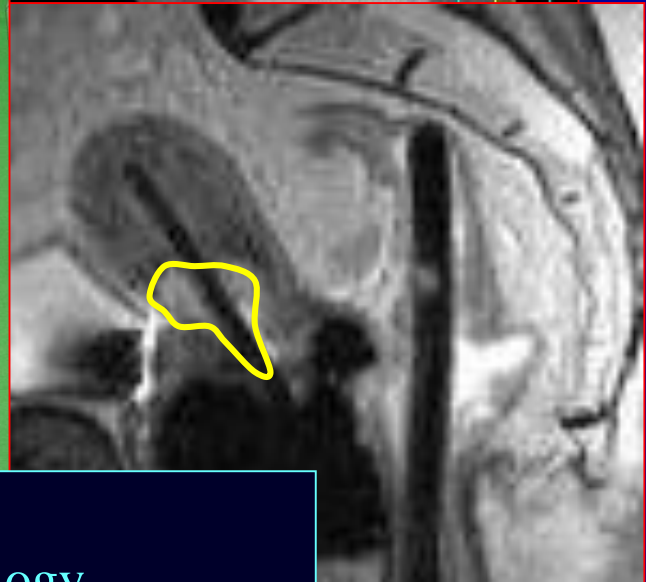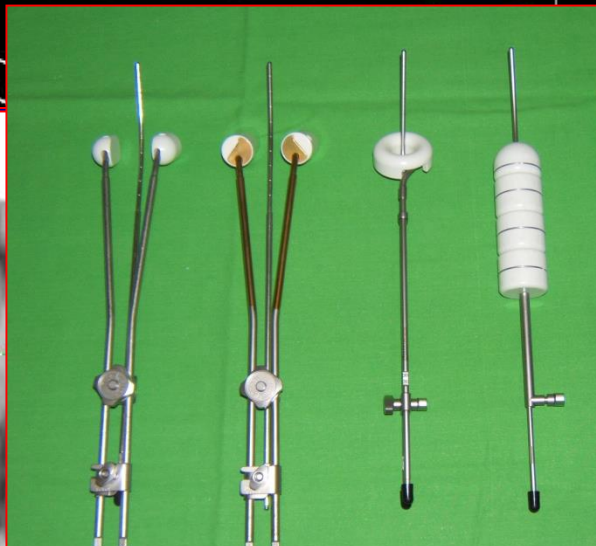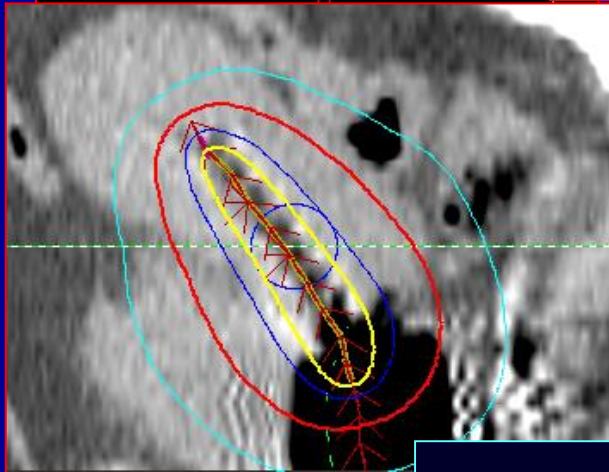
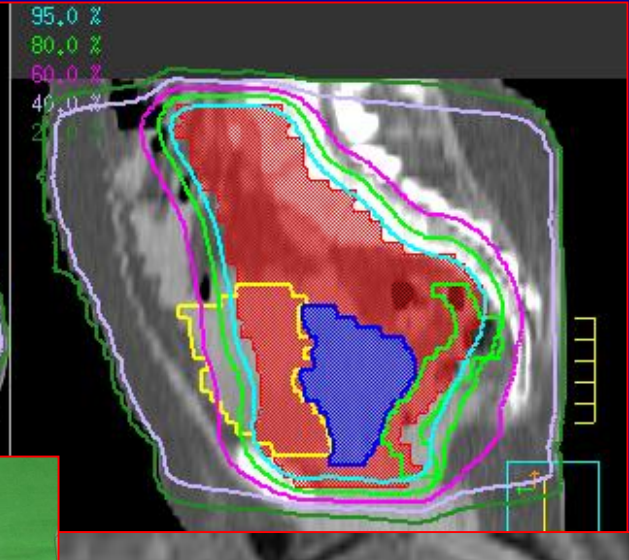
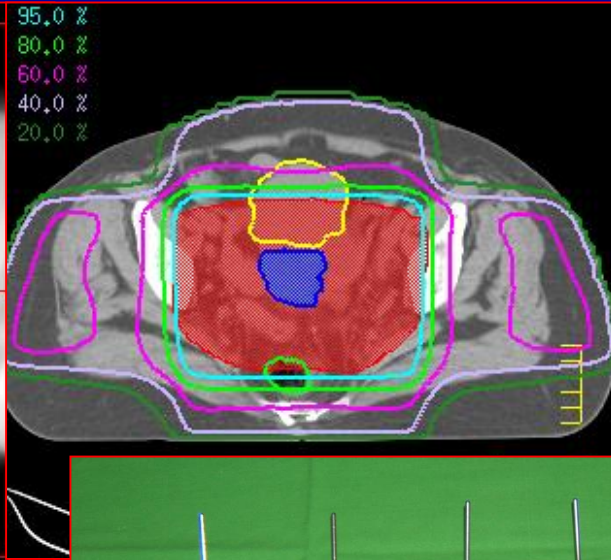
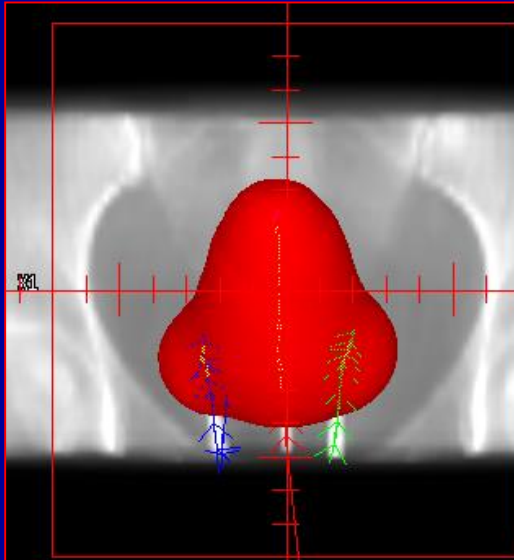


# Management of gynaecological tumours



Csaba Polgár –  
National Institute of Oncology,  
Semmelweis University, Dept. of Oncology

# Incidence of malignant tumours (2007 és 2014)

## Females

Localisation		Incidence								
		2008	2009	2010	2011	2012	2013	2014	<u>2017</u>	
1	Skin (Non-melanoma; C44)	6673	6622	6258	7 993	7687	7936	9061		
2	Breast	6938	6861	6610	7 767	7733	7775	7880		
3	Colorectal	4582	4457	4373	4 942	4886	4793	4902		
4	Lung & Bronchus	4305	4103	3930	4 606	4404	4573	4675		
5	Lymphoproliferative dis.	1873	1951	1845	2 066	2229	2142	2177		
6	Uterine corpus (C54-C55)	1365	1378	1299	1 648	1523	1548	1694	1640	+275
7	Ovarium (C56)	1261	1185	1104	1 410	1421	1402	1357	1383	+122
8	Skin melanoma	1085	1059	1031	1156	1239	1258	1234		
9	Stomach	1154	1062	1000	1 129	1089	1048	1000		
10	Cervix uteri (C53)	1076	981	932	1 159	1060	1121	1154	983	-93
	<b>All:</b>	<b>41218</b>	<b>39874</b>	<b>38680</b>	<b>45681</b>	<b>45227</b>	<b>45778</b>	<b>48052</b>	<b><u>2017</u> - Vulva: 228 Vagina: 124</b>	
	<b>All (wo C44):</b>	<b>34 544</b>	<b>33 252</b>	<b>32 404</b>	<b>37 688</b>	<b>37540</b>	<b>37842</b>	<b>38991</b>		

# Annual mortality (2004-2013)

## Females

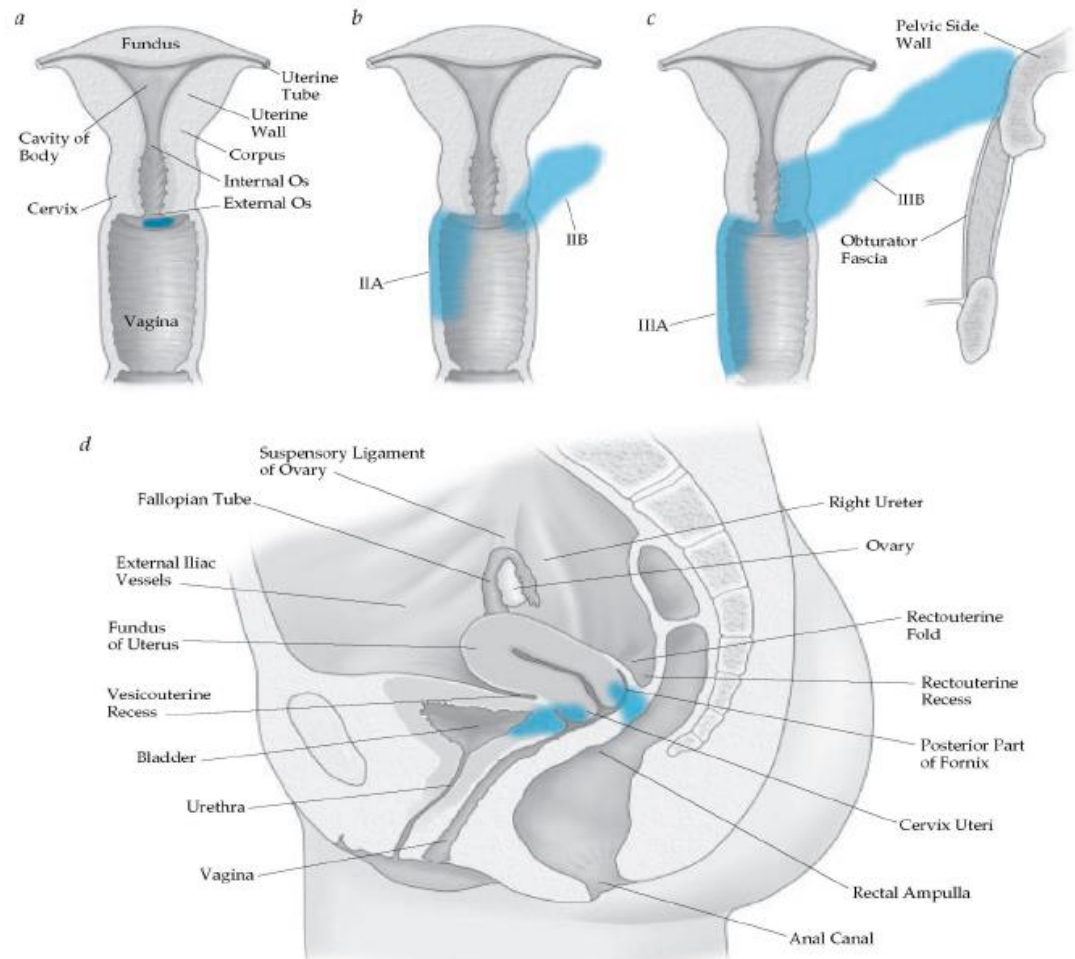
Localisation		Mortality										
		2004	2005	2006	2007	2008	2009	2010	2011	2012	2013	
1	Lung & Bronchus	2408	2235	2321	2566	2733	2766	2 907	2975	3133	3173	
2	Colorectal	2261	2095	2141	2158	2190	2187	2 261	2219	2274	2242	
3	Breast	2285	2085	2059	2045	2108	2169	2 011	2138	2096	2167	
4	Pancreas	828	803	873	909	895	940	985	908	1053	1033	
5	Lymphoproliferative	945	857	802	860	835	820	834	855	852	831	
6	Ovarium (C56)	666	612	610	660	687	687	675	700	700	739	+73
7	Stomach	857	738	744	720	744	822	694	746	732	677	
8	Gallbladder	560	467	465	439	428	457	420	428	434	418	
9	Uterine corpus (C54-C55)	402	375	385	357	334	377	386	436	429	417	+15
10	Cervix uteri (C53)	493	416	420	424	418	396	379	414	426	405	-88
	<b>All:</b>	<b>14660</b>	<b>13481</b>	<b>13669</b>	<b>13926</b>	<b>14212</b>	<b>14359</b>	<b>14 428</b>	<b>14991</b>	<b>14945</b>	<b>14933</b>	

# Staging of Cervical Cancer - FIGO 2009

## FIGO stage classification of cervical cancers

St. 0	Carcinoma in situ
St. I	Tumour is confined to the cervix
St. I/A1	Stromal invasion depth is <3 mm, horizontal spread is <7 mm
St. I/A2	Invasion depth is 3-5 mm, horizontal spread is <7 mm
St. I/B1	Macroscopic tumour, but $\leq 4$ cm
St. I/B2	"Bulky" tumour, >4 cm
St. II.	Tumour invades past the uterus, but not past the pelvic wall or to the lowest 1/3 of the vagina
St. II/A	Upper third of the vagina is involved
St. II/A1	Macroscopic tumour, but $\leq 4$ cm
St. II/A2	"Bulky" tumour, >4 cm
St. II/B	The tumour invades the parametria, but does not spread to the pelvic wall
St. III/A	Lower two thirds of the vagina are involved
St. III/B	The tumour invades the parametria to the pelvic wall; hydronephrosis is present
St. IV/A	Tumour infiltrates the bladder and/or rectum
St. IV/B	Distant metastases are present

## Cervix Cancer FIGO Staging








# Cervical Cancer – Symptoms, Diagnosis, Staging

- **Smptoms:**

- Early: vaginal discharge, contact bleeding
- Late: bloody discharge, pain, weight loss, fatigue, anaemia

- **Diagnostic work-up, staging:**

- Cytology, conisation, excisional biopsy  histology
- Physical exam (incl. RDE!)  local extent
- Pelvic MRI  local/regional spread
- PET/CT  PAO & distant metastases
- Cystoscopy/Rectoscopy  suspicion of bladder/rectal invasion



# Cervical Cancer – Prognostic Factors

- Stage
  - 5-year survival: St. 0-I/A1: 100%, St. I/A2: 95-100%, St. I/B: 82-90%, St. II/A: 75%, St. II/B: 60-65%, St. III: 25-50%, St. IV/A: 18-35%
- Lymph node status (pN)
  - PIL: St. I/A1: 0-1%, St. I/A2: 5-7%, St. I/B: 11-16%, St. II: 27-45%, St. III: 42-60%
  - PAO: St. I/B: 6%, St. II: 13-19%, St. III: 20-29%, St. IV: > 30%
- Histological type
  - (squamous cell cc., adenocc., adenosquamosus cc.)
- Histological Grade
- Lympho-Vascular Invasion (LVI)
- Surgical margin
- Hgb-level, anaemia
- Overall treatment time
  - Radiotherapy < 8 weeks

# Cervical Cancer - Management:

- **St. 0-I/A1:**
  - Surgery alone (hysterectomy, trachelectomy, conisation)
  - Surgery contraindicated: definitive RT (brachytherapy)
- **St. I/A2-I/B1:**
  - Wertheim-operation ± postop. RT
  - Preop. RT + Wertheim-operation ± postop. RT
  - Surgery contraindicated: definitive, accelerated RT
- **St. I/B2-II/A-II/B (early):**
  - Definitive, simultaneous RCT
  - Wertheim-operation + postop. RT or RCT
  - Preop. RT + Wertheim-operation + postop. RT or RCT
  - Neoadjuvant CT + Wertheim-operation + postop. RT
- **St. II/B-III/A-B-IV/A:**
  - Definitive, simultaneous RCT
- **St. IV/B:**
  - Palliative RT + CT (cisplatin-paclitaxel-bevacuzimab)

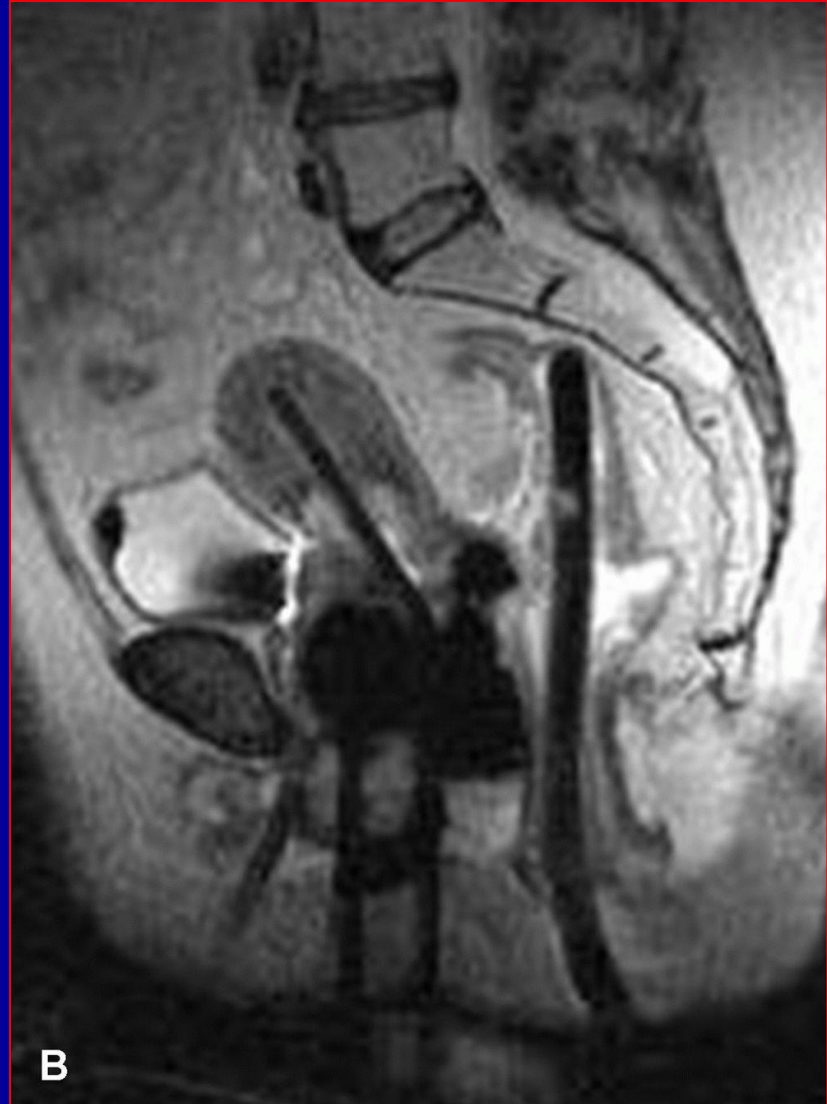St. 0-I/B1:  
Surgical  
treatment

St. I/B2-IV/A:  
Radio-  
chemotherapy

St. IV/B:  
Palliative  
RT & CT

## Cervical Cancer – Indications of Radiotherapy

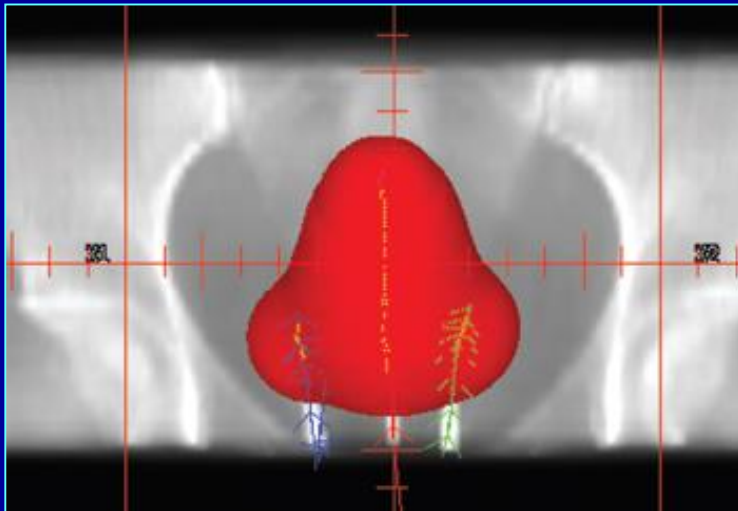
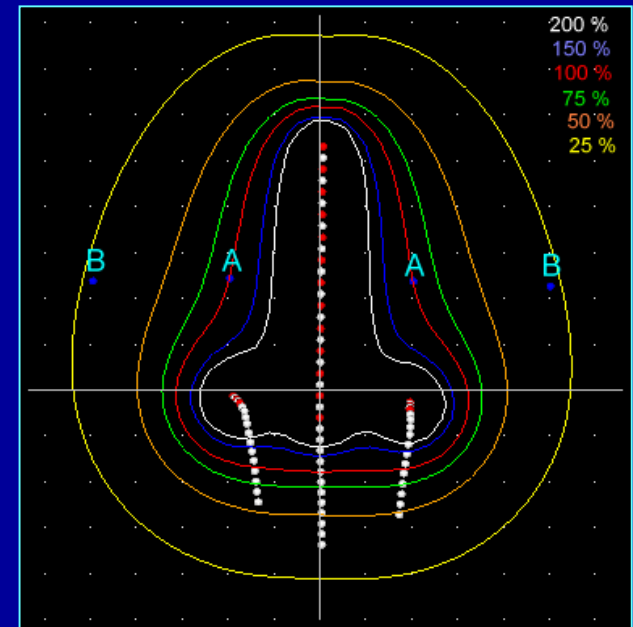
- Curative:
  - Preoperative
  - Postoperative
  - Definitive (primary)
    - RT alone
    - Simultaneous RCT
- Palliative





# Rationale for Preoperative Radiotherapy:

- Tumour down-sizing, down-staging
- Devitalisation of malignant cells, decreasing the chance of tumour spread during surgery
- Pathological complete remission (pCR)
- In case of pCR postop. RT can be omitted, less posttreatment side-effects.



## Postoperative RT according to risk groups:

### Low-risk group:


- Positive surgical margins (R1/R2) and/or
- Positive LN status (pN1) and/or
- Histologically proved parametral involvement



**POSTOP. RCT**

### Intermediate-risk group:


- Close surgical margins ( $\leq 3$  mm) and/or
- Stromal invasion  $\geq 10$  mm and/or
- Primary tumour size  $> 4$  cm and/or
- LVI and/or
- Grade III tumour and/or
- Adenocarcinoma



**POSTOP. RT**

### High-risk group:

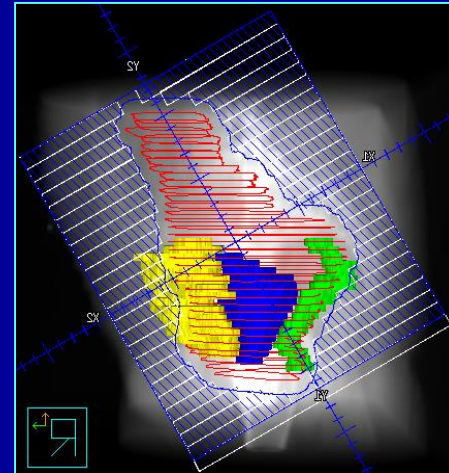
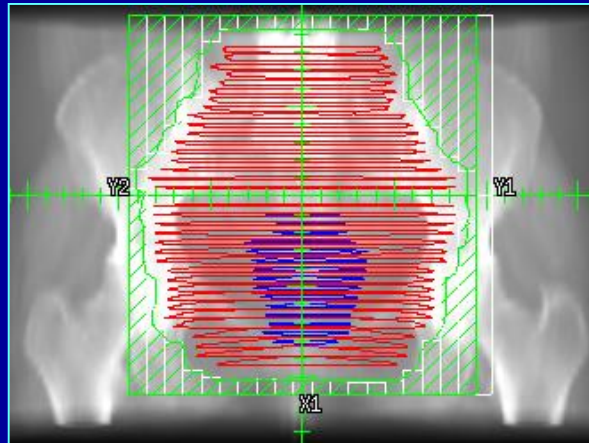
- Lack of above risk factors
- Tumour free specimen (pCR & pN0)



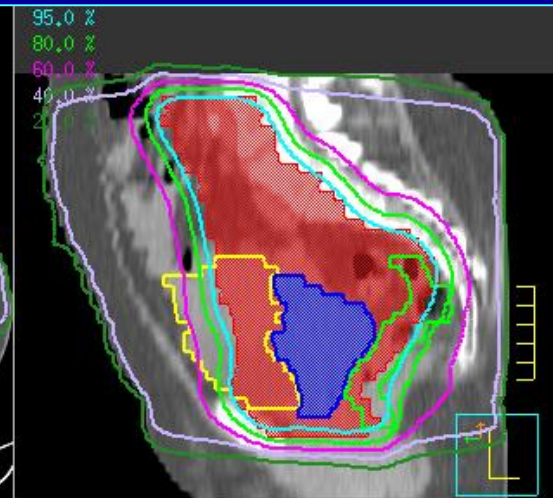
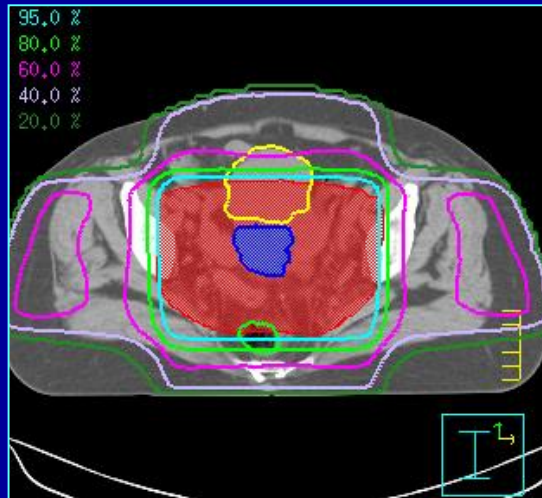
**OBSERVATION**

# Pelvic external beam RT - 3D conformal radiotherapy (3D-CRT), 4-field box technique

Field arrangement



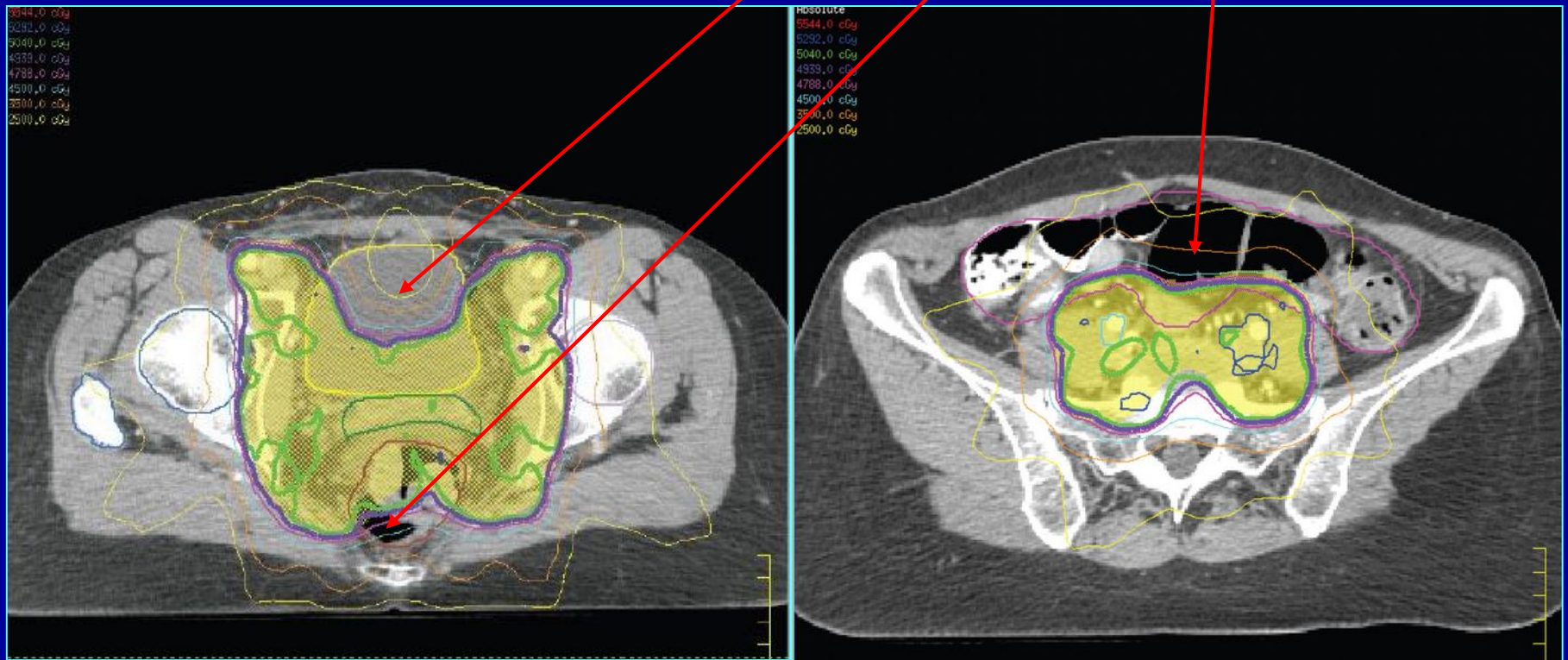
Dose distribution



Blue: uterus; green: rectum; yellow: bladder; red: PTV

# Pelvic external beam RT - Intensity-modulated radiotherapy (IMRT)

Significantly lower dose to bladder, rectum and bowels!



# Indication and doses of primary radiotherapy and radiochemotherapy according to clinical stage –

## NIO protocol

Stage	Treatment	Teletherapy dose	Brachytherapy dose
St. I/A1	RT: brachytherapy alone	-	6 x 7 Gy HDR AL (1 fraction/week)
St. I/A2- I/B1	RT: combined, accelerated RT (brachy- + teletherapy)	45 Gy (accelerated treatment, 4 fractions/week)	6 x 7 Gy HDR AL (accelerated treatment, 1 fraction/week)
St. I/B2- IV/A	RKT: weekly 40 mg/m <sup>2</sup> cisplatin + teletherapy + boost brachytherapy	45-50.4 Gy ± 10 Gy boost to parametria	3-4 x 7 Gy HDR AL boost (after teletherapy)



## Indications of radiochemotherapy:

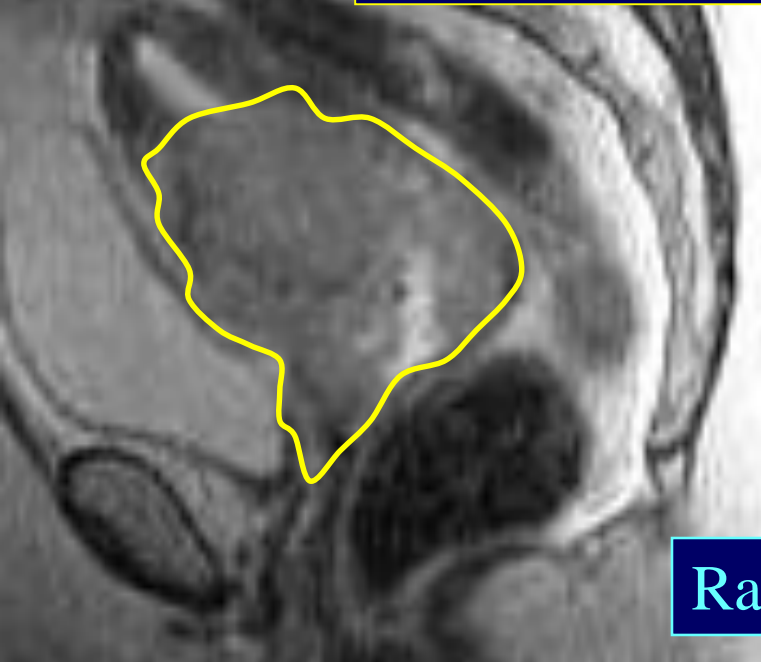
- (Preoperative)
- Definitive (primary)
- Postoperative

## Standard radiochemotherapy protocols:


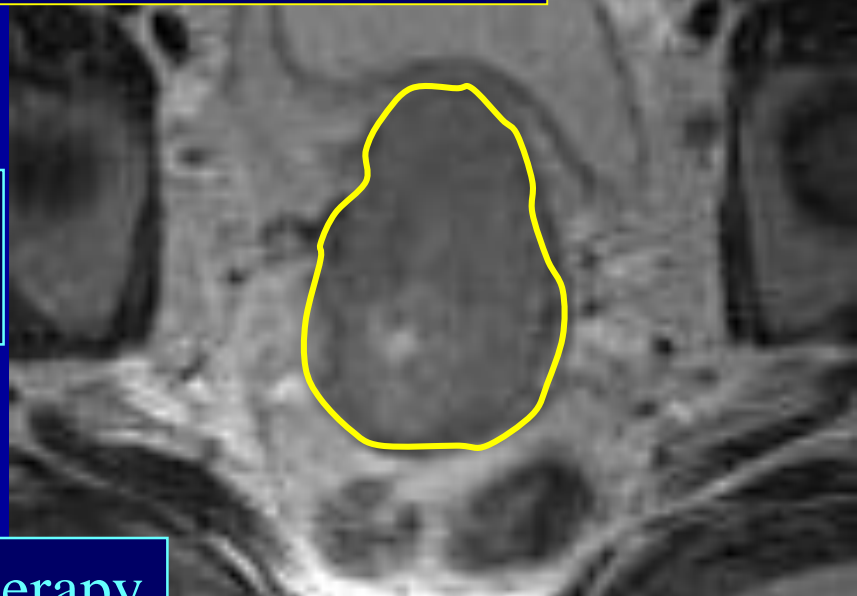
- Radiotherapy:
  - 45-50.4 Gy (25-28x 1.8 Gy/die) pelvic RT (5-5.5 hét)
- Weekly cisplatin:
  - 40 mg/m<sup>2</sup> CDDP weekly (5-6 cycles)
- Cisplatin-5-FU:
  - 70 mg/m<sup>2</sup> CDDP (Day 1) + 1000 mg/m<sup>2</sup> 5-FU (Days 1-4)  
(2 cycles during 1<sup>st.</sup> and 5<sup>th.</sup> weeks of RT)



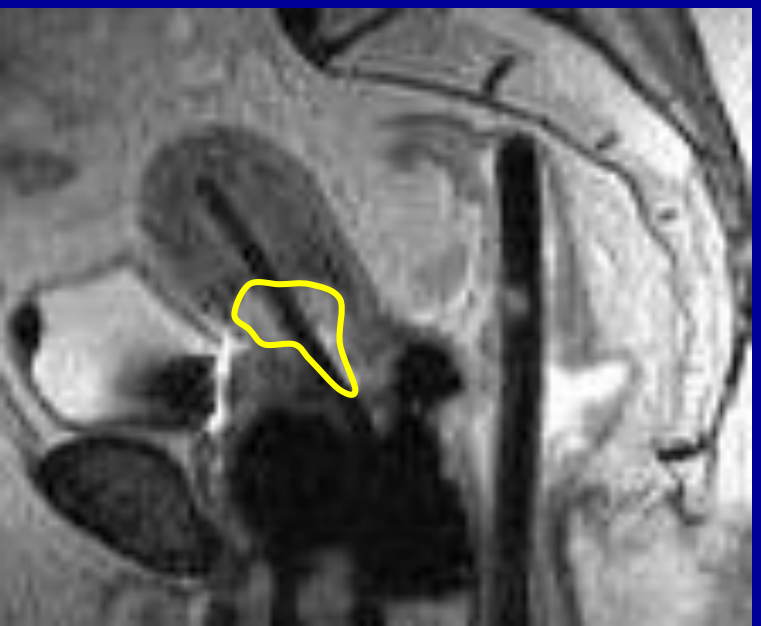
# Primary radiochemotherapy of cervical cancer



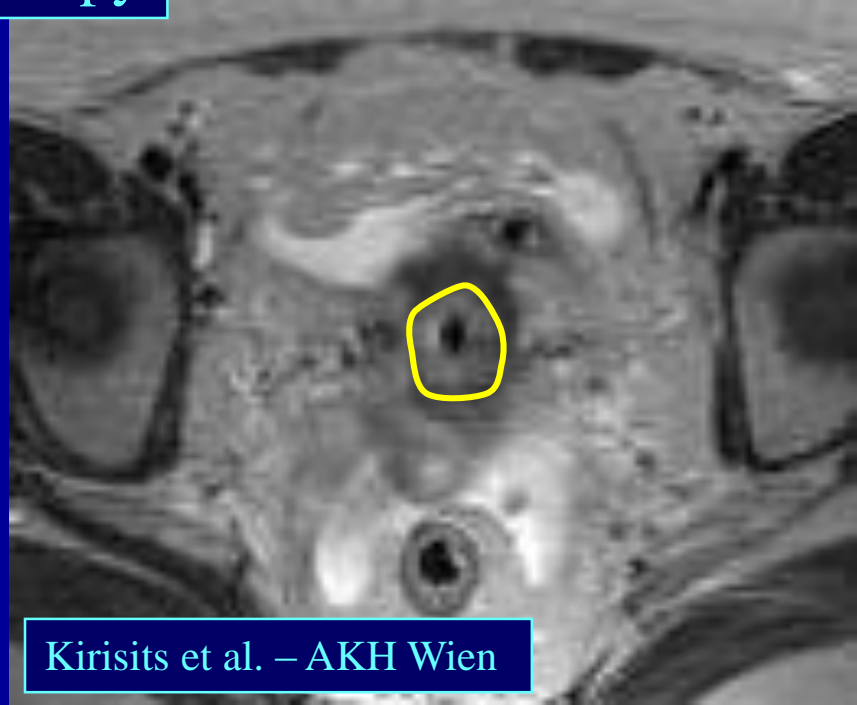Before  
treatment



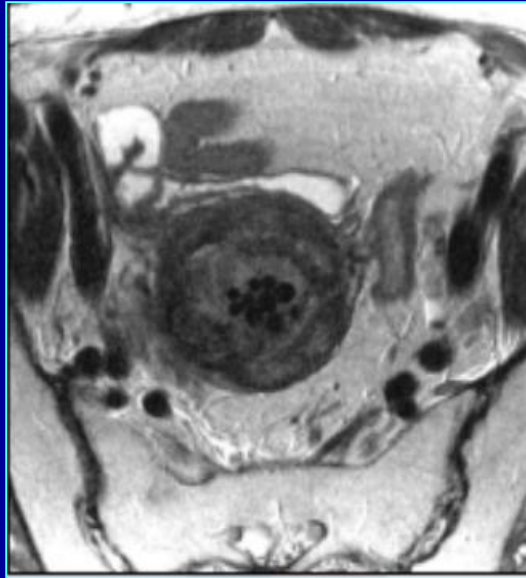
Radiochemotherapy



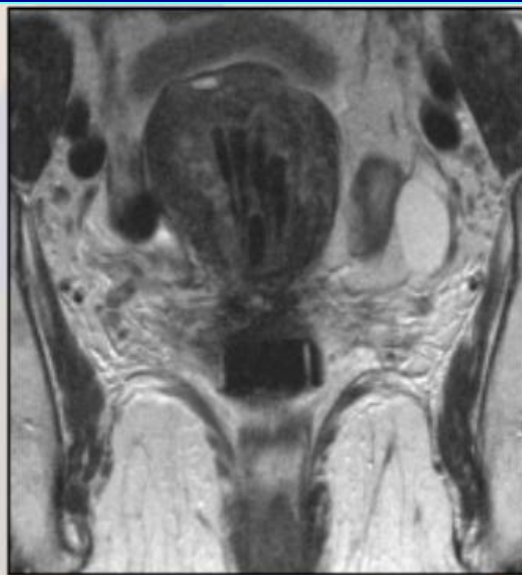
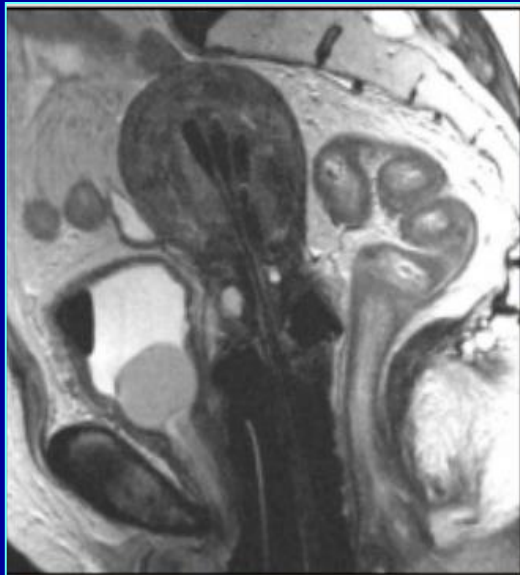
HDR-BT  
boost



# Endometrial cancer FIGO & TNM staging – FIGO 2009








70%



TNM	FIGO	
Tx		No evidence of primary tumour
0		No primary tumour
Tis	0	Carcinoma in situ (preinvasive cancer)
T1	I	<b>Tumour is confined to the endometrium</b>
T1a	IA	Tumour infiltrates less than half of the myometrium
T1b	IB	Tumour infiltrates at least half of the myometrium
T2	II	<b>Tumour infiltrates cervical stroma, but is confined to the uterus</b>
T3	III	<b>Local and/or regional tumour invasion</b>
T3a	IIIA	Tumour infiltrates the peritoneal surface of the uterus and/or appendices
T3b	IIIB	Vaginal and/or parametrial involvement
N1	IIIC	Tumour has metastasised to the pelvic and/or the paraaortic lymph nodes
	IIIC1	Tumour has metastasised to the pelvic lymph nodes
	IIIC2	Tumour has metastasised to the paraaortic lymph nodes
	IV	<b>Tumour infiltrates bladder and/or rectal mucosa and/or tumour has metastasised to distant organs</b>
T4	IVA	Tumour infiltrates bladder and/or rectal mucosa
M1	IVB	T Distant metastases are present (abdominal cavity and/or inguinal lymph node metastases)

# Endometrial cancer – Symptoms, Diagnosis, and Staging

- Symptoms:
  - Postmenopausal vaginal bleeding
- Diagnostic work-up, staging
  - Hysteroscopy, fractionated abrasion  histological diagnosis
  - Physical exam. (incl. RDE!)  local extent
  - Pelvic MRI  local/regional spread
  - CT, PET/CT  PAO & distant metastases
  - Cystoscopy/Rectoscopy  suspicion of bladder/rectal invasion

# Management of Endometrial Cancer

## Primary treatment = Surgery

- Early stage:
  - TAH + BSO +/- LAD\*
  - Peritoneal revision
  - Advanced stages:
    - Debulking surgery
- +/- Adjuvant RT/CT according to final histology report

\*TAH = Total Abdominal Hysterectomy  
BSO = Bilateral Salpingo-Oophorectomy  
LAD = Lymphadenectomy

# Management of Endometrial Cancer:

- **St. I-II:**
  - TAH + BSO +/- LAD +/- postop. RT
  - Preop. RT + TAH + BSO +/- LAD +/- postop. RT
  - If surgery contraindicated: primary RT
- **St. III:**
  - Surgery + postop. RT + systemic therapy (chemo- or hormone therapy)
  - If surgery contraindicated: primary RT/RCT
- **St. IV/A:**
  - Primary RT + systemic therapy
  - Exenteration
- **St. IV/B:**
  - Palliative RT + systemic therapy (CT + HT)

## Indications of radiotherapy for endometrial cancer:

- Curative:
  - (Preoperative)
  - Postoperative
  - Definitive (primary)
    - RT alone
    - Simultaneous RCT
- Palliative



## Histological types

- Type 1 histology: endometrioid adenocarcinoma
- Type 2 histology: clear cell carcinoma  
papillary/serous carcinoma  
carcinosarcoma

## Risk groups

### Low risk

- G1/2 endometrioid carcinoma and  
≤ 50% myometrial invasion

### Intermediate risk

- G1/2 endometrioid carcinoma and  
> 50% myometrial invasion  
- G3 endometrioid carcinoma and  
≤ 50% myometrial invasion

### High risk

- G3 endometrioid carcinoma and  
>50% myometrial invasion  
- All Type 2 histology

## Postoperative RT of endometrial cancer— NIO protocol

Postoperative radiotherapy of endometrial tumours, according to stage	
Characteristics	Postoperative treatment
I/A, G1-2	NOT REQUIRED!
I/A, G3	Vaginal brachytherapy
I/B, G1-2	LAD was performed and is negative: Vaginal brachytherapy
	LAD was not performed: Vaginal + pelvic radiotherapy
I/B, G3, II, any G	Vaginal + pelvic radiotherapy
III/A	Vaginal + pelvic radiotherapy Systemic treatment (hormone or chemotherapy)
III/B, III/C, IV/A, IV/B	Vaginal + pelvic radiotherapy (if stage III/C2 + PAO radiotherapy) Systemic treatment (hormone or chemotherapy)

G: grade; PAO: paraaortic lymph node region

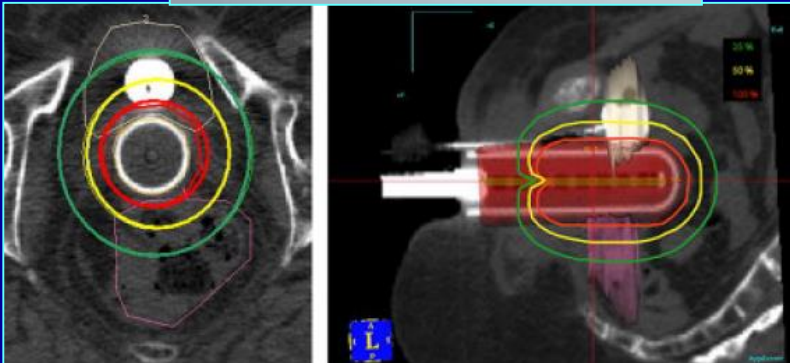
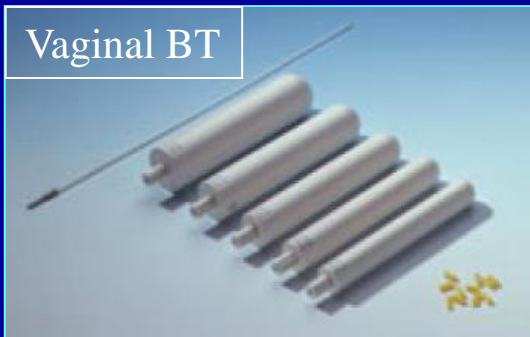**Papillary/serous and clear-cell cc: Vaginal + pelvic RT in each case!**

# Postoperative RT of endometrial cancer– NIO protocol

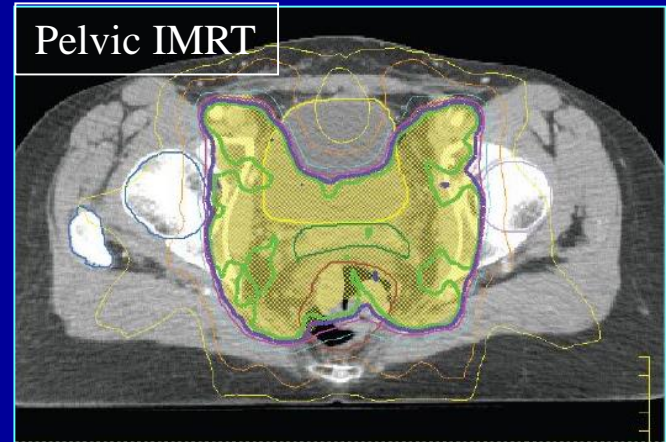
## Radiotherapy types and dosage for patients who did not receive preoperative radiotherapy

Vaginal brachytherapy only	3x7 Gy at a depth of 0.5 cm, usually at an active length of 5 cm from the closing line
Combined pelvic EBRT + vaginal brachytherapy	3x5 Gy at a depth of 0.5 cm, usually at an active length of 5 cm from the closing line, followed by 45-50.4 Gy (1.8-2 Gy/day) EBRT
Paraaortic + pelvic radiotherapy (if PAO lymph nodes are positive)	Pelvic + PAO region radiotherapy with 3-D conformal planning or IMRT, with a total dose of 45-50.4 Gy (1.8 Gy/day)

Vaginal BT



Pelvic IMRT



# Primary radiotherapy of endometrial cancer – Only in case of contraindicated surgery!

## The definitive radiotherapy of endometrial tumours

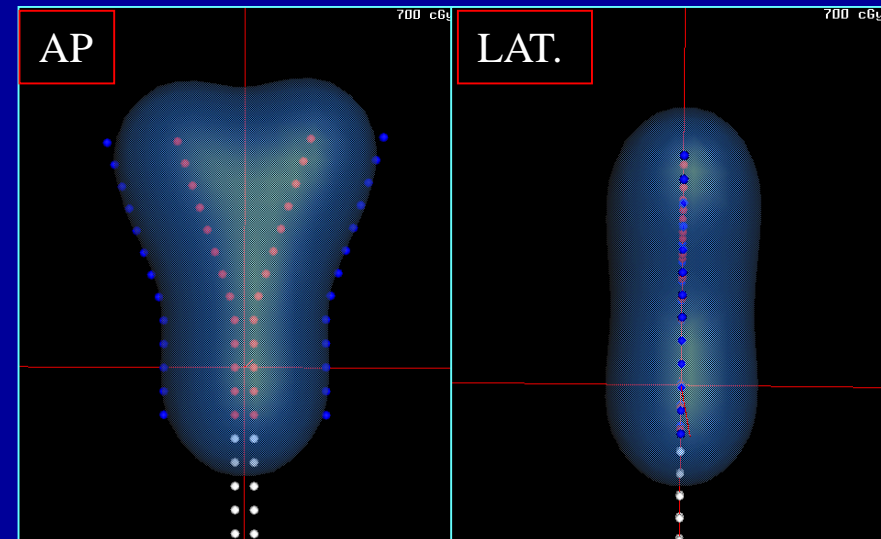
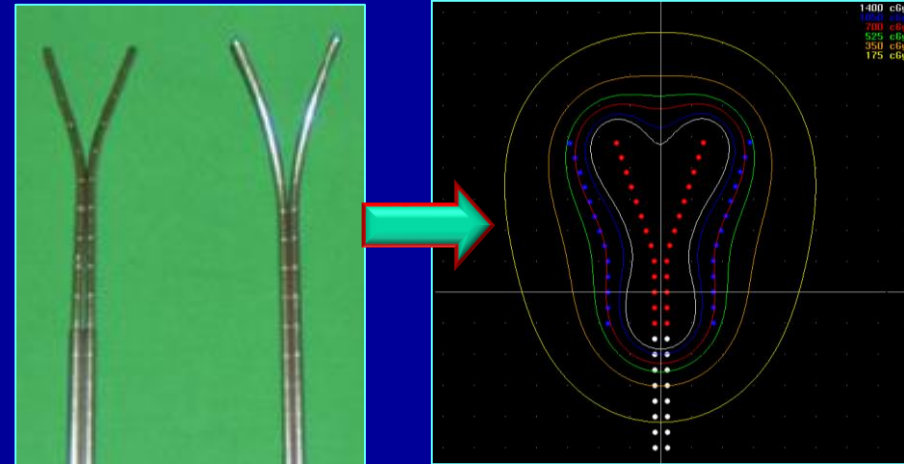
Accelerated treatment: 1x IC weekly,  
on other days, 4 x EXT.

ICBT	5x7 Gy calculated for the endometrial surface
EBRT	46 Gy with 4-field box technique; after 30 Gy, half-beam block technique or IMRT

## Single intracavitary radiotherapy

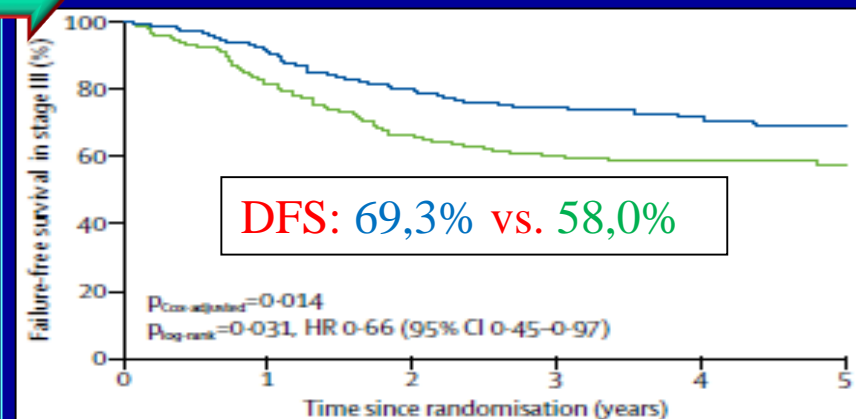
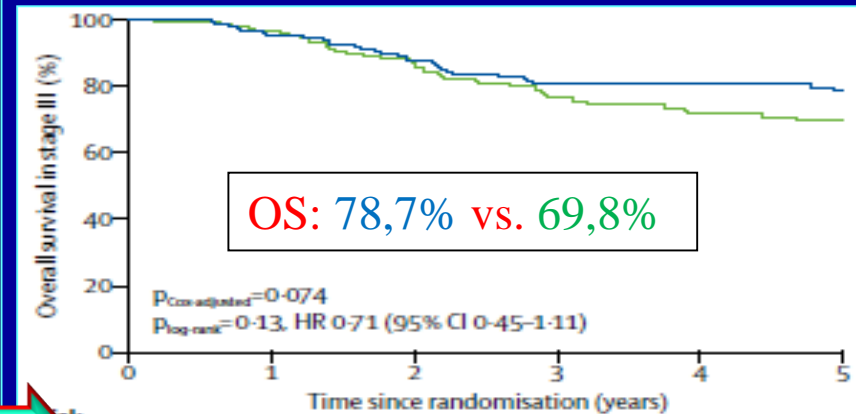
ICBT	6x7 Gy calculated for the endometrial surface
------	---

ICBT: intracavitary brachytherapy; EBRT: external beam radiotherapy




## Drug treatment of endometrial cancer:

- **Chemotherapy (St. III-IV):**
  - CAP (Cyclophosphamid-Adriamycin-Platina)
  - Carboplatin-Paclitaxel
- **Postop. Radiochemotherapy (St. III):**
  - Simultaneous Cisplatin during RT (Week 1 & 4)
  - + 4 cycles of adjuvant Carboplatin-Paclitaxel
- **Hormone therapy:**
  - Gestagenes (Megace)
  - Anti-estrogenes (Tamoxifen)



# Staging of ovarian cancer



## Symptoms, diagnosis, and staging

### Symptoms:

- Early: none!
- Late: bloating, ascites, abdominal discomfort
- Most commonly recognized in advanced stage III/C!

### Diagnostic work-up, and staging:

- CA-125 tumour marker
- Physical exam. (RDE: Douglas's pouch!)
- Vaginal US
- Pelvic CT/MRI
- Irresectable tumour: core-biopsy

<b>St. I</b>	<b>The tumour is confined to the ovaries</b>
<b>IA</b>	Tumour is limited to one ovary, capsule intact
<b>IB</b>	Tumour is present in both ovaries, capsule intact
<b>IC</b>	Tumour is present in one or both ovaries, and
<b>IC1</b>	Surgical-artificial spill is present
<b>IC2</b>	Capsule has ruptured before surgery
<b>IC3</b>	Ascites or positive intraperitoneal cytology are present
<b>St. II</b>	<b>Tumour is present in one or both ovaries, extension includes other pelvic structures</b>
<b>IIA</b>	Tumour has spread to the uterus or the fallopian tubes
<b>IIB</b>	Tumour has spread to intraperitoneal pelvic structures
<b>St. III</b>	<b>Tumour is present in one or both ovaries, with extension to extrapelvic peritoneal and/or retroperitoneal lymph nodes</b>
<b>III/A1</b>	Positive retroperitoneal lymph nodes (III/A1 (i) < 10 mm III/A1 (ii) > 10 mm)
<b>III/A2</b>	Microscopic extrapelvic peritoneal metastases + positive lymph node status
<b>III/B</b>	Macroscopic < 2 cm extrapelvic peritoneal metastasis (liver/spleen) and/or positive retroperitoneal lymph nodes
<b>III/C</b>	Macroscopic (> 2 cm) extrapelvic peritoneal metastasis (liver/spleen) and/or positive retroperitoneal lymph nodes
<b>St. IV</b>	<b>Distant metastases present beyond the peritoneal area</b>
<b>IV/A</b>	Pleural effusion contains tumour cells
<b>IV/B</b>	Distant metastasis (liver, lung, spleen; inguinal or extra-abdominal lymph node metastases)



# Management of ovarian cancer

## Primary treatment = Surgery + Chemotherapy

### - Staging laparotomy:

- TAH + BSO + ROM + LAD\*

- Peritoneal revision

- Cytology of peritoneal washing fluid

- Optimal surgery: Rate of R0 resection >66%

- Suboptimal surgery: 3-4 cycles of CT  interval laparotomy

\*TAH = Total Abdominal Hysterectomy  
BSO = Bilateral Salpingo-Oophorectomy  
ROM = Resection of Omentum Majoris  
LAD = Lymphadenectomy

### - Adjuvant CT:

- Carboplatin-Paclitaxel (Taxol)


- 2<sup>nd</sup>. & 3<sup>rd</sup>. line:


- Platinum resistant: Bevacizumab (Avastin)

- Platinum sensitive: Platina reinduction, Docetaxel (Taxotere), Topotecan (Hycamtin), liposomal Doxorubicin (Caelyx), PARP-inhibitors (Olaparib, Rucaparib),

# Indications of radiotherapy for ovarian cancer

- Adjuvant
- Salvage/consolidating
- Palliative

- Lack of level 1-2 evidencies
  - Previous clinical studies used CT without platinum/taxanes
  - No definitive guidelines
- 
- Indication: individual decision limited to cases with contraindication of chemotherapy

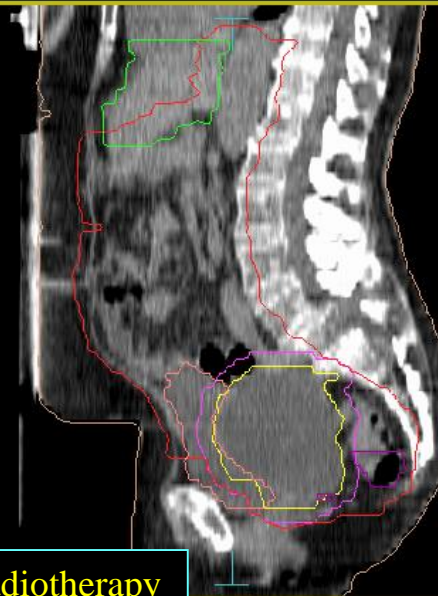
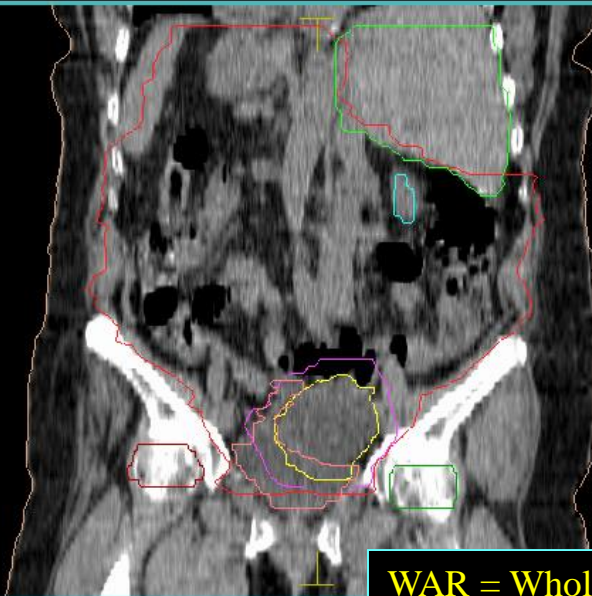
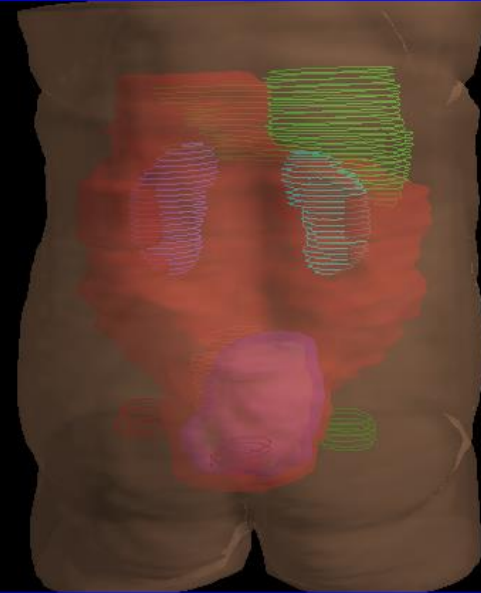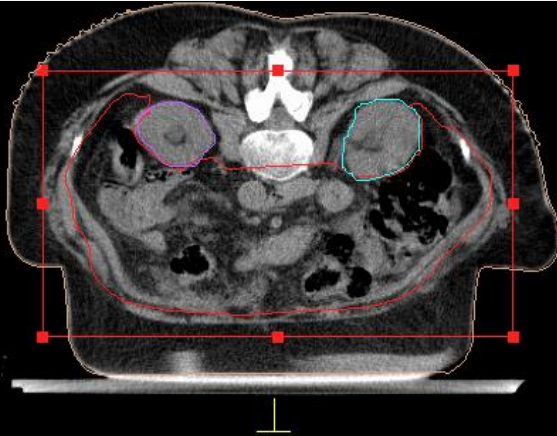- 
- Distant metastases (e.g. supraclavicular met.)
  - Persistent or recurrent pelvic tumour mass
  - Paraaortic LN metastases
  - Whole abdominal RT: only in good general condition (ECOG: 0-1)

# Whole Abdominal Radiotherapy = WAR

Dose:

Whole abdomen: 25-30 Gy (1-1.5 Gy/fr.)

Pelvis: 45 Gy (1.8-2 Gy/fr.)



WAR = Whole Abdominal Radiotherapy

# Staging of vulvar cancer

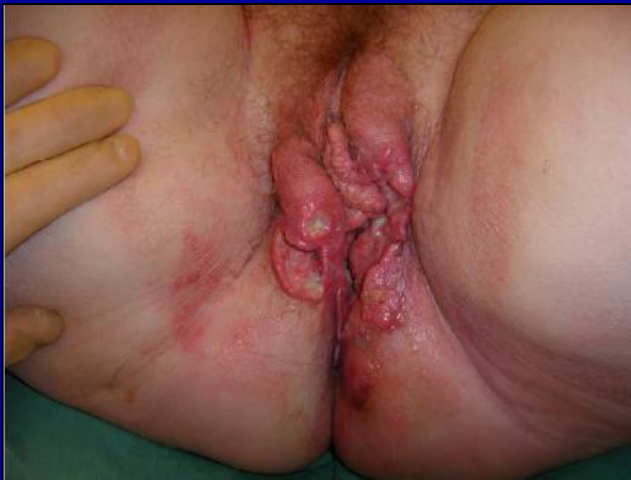## Symptoms, diagnosis, and staging

### Symptoms:

- Exophytic or exulcerated tumours of labia minora or majora
- Skin discharge, itching, bleeding

### Diagnostic work-up and staging:

- Physical exam. (inguinal lymphatic region + rectovaginal exam.)
- Inguinal US
- Pelvic CT/MRI
- Incisional biopsy → Histological diagnosis



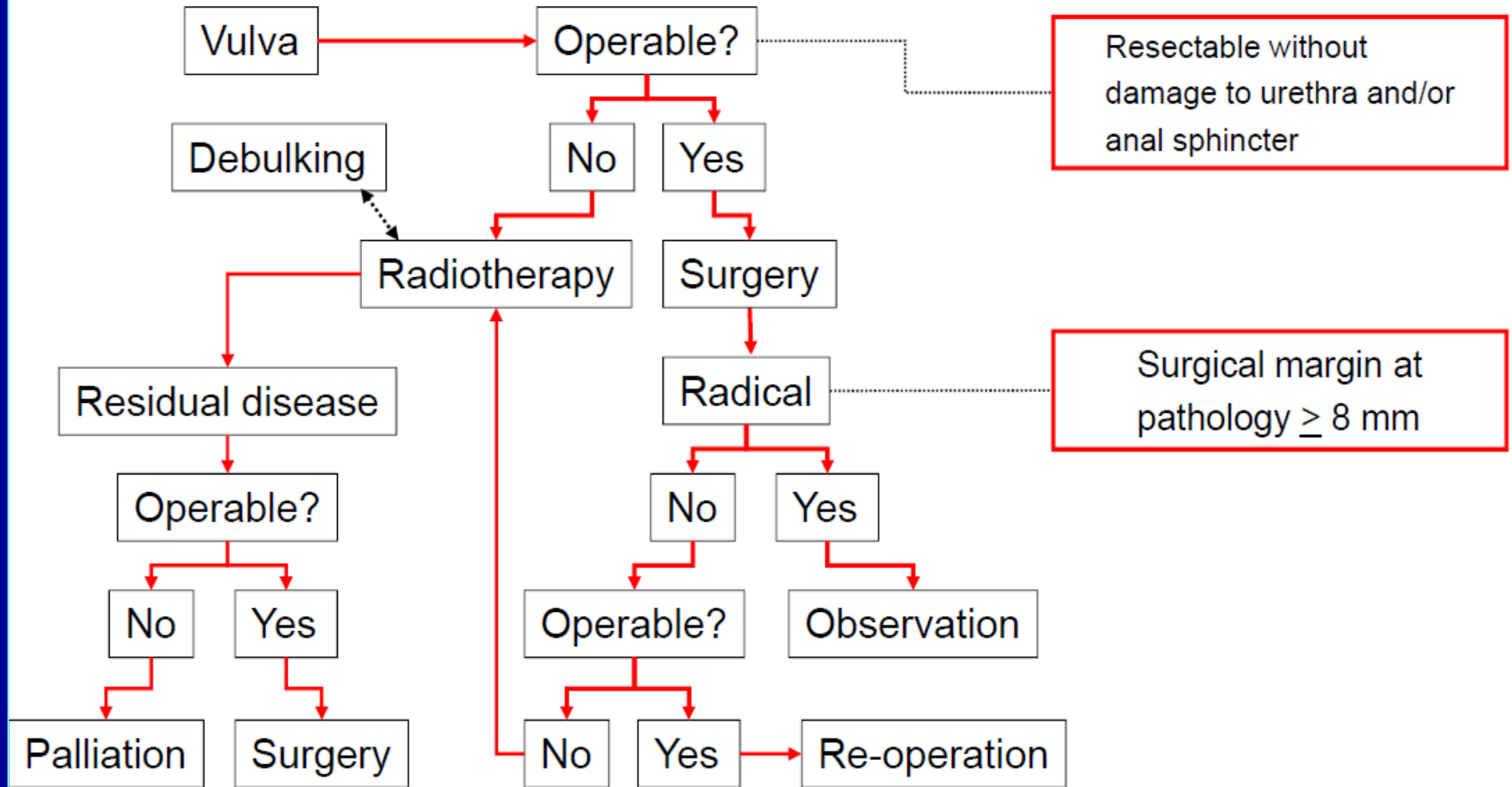
St.		
<b>T Primary tumour</b>		
Tis	0	Carcinoma in situ
T1	1a	Tumour diameter is <2 cm, depth of invasion does not exceed 1 mm (microinvasive cancer)
	1b	Tumour diameter is <2 cm, depth of invasion is >1 mm
T2	II	Tumour diameter is >2 cm
T3	III	Tumour invades the urethra, and/or the vagina, perineum, anus; unilateral inguinal metastasis
T4	IVa	Tumour invades rectal and/or bladder mucosa, the mucosa of the upper urethral segment, and/or metastasises to the pelvic bone; bilateral inguinal metastasis
	IVb	distant metastases, abdominal lymph node positivity
<b>N Lymph node status</b>		
NX		Lymph node status cannot be assessed
N0		No lymph node metastases
N1		Unilateral inguinal lymph node metastases
N2		Bilateral inguinal lymph node metastases
<b>M Distant metastases</b>		
MX		Distant metastases cannot be assessed
M0		No distant metastases
M1		Distant metastases are present (pelvic lymph node metastases are also considered M1)

## Management of vulvar cancer

### Primary treatment = Surgery

- Stage I/A:
  - Local wide excision
- Stage I/B:
  - Radical vulvectomy + bilateral inguinal dissection
- +/- Adjuvant RT

# Management of vulvar cancer

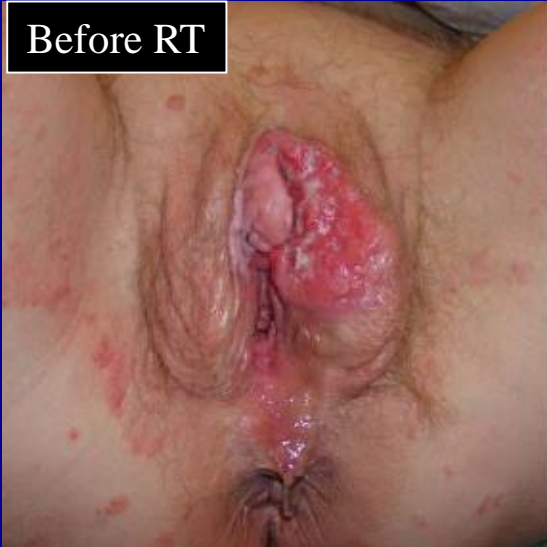



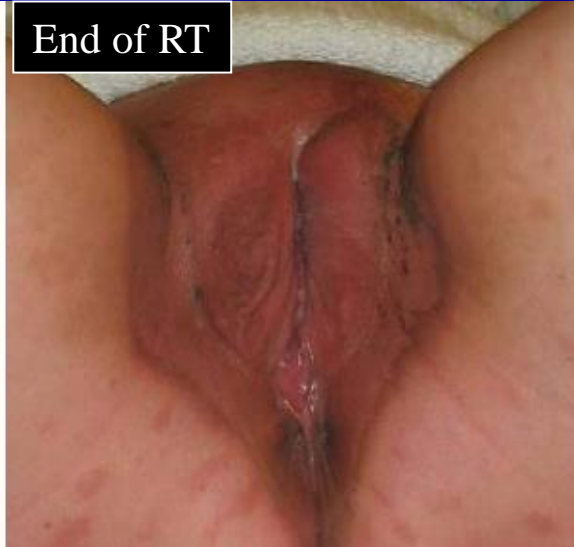## Radiotherapy of vulvar cancer

- Postoperative
- Primary RT/RKT
- Palliative

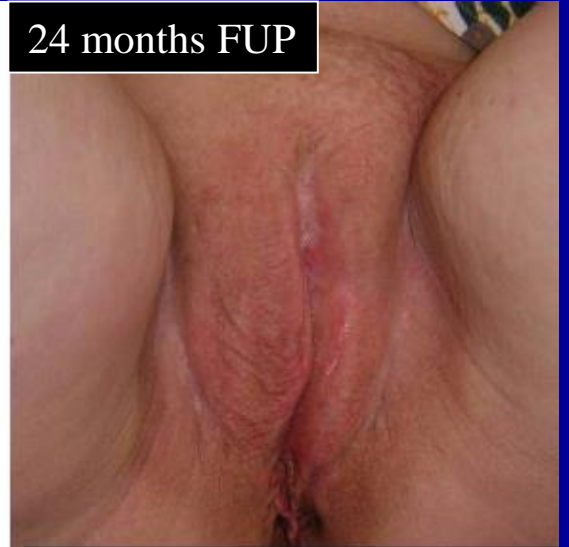Before RT



End of RT



24 months FUP



# Postoperative radiotherapy of vulvar cancer

## NCCN guideline for local and inguinal RT

Positive margins for invasive disease

→ Adjuvant EBRT<sup>i</sup>

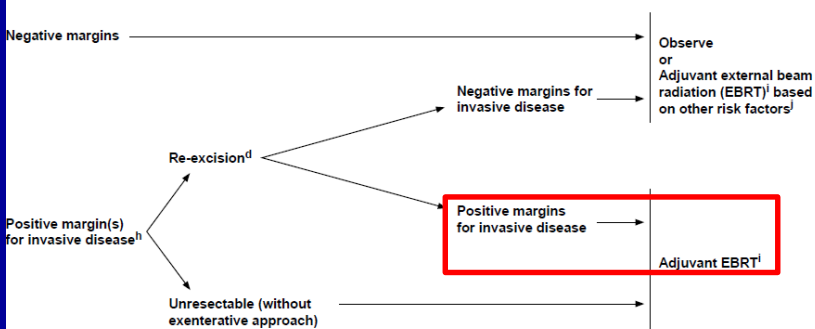
EBRT<sup>i</sup> ± concurrent chemotherapy<sup>l</sup>  
(especially if ≥2 LNs positive or 1 LN positive with >2 mm metastasis)  
(category 1 for radiation)

NCCN National Comprehensive Cancer Network\*  
NCCN Guidelines Version 1.2017  
Vulvar Cancer (Squamous Cell Carcinoma)

[NCCN Guidelines Index](#)  
[Table of Contents](#)  
[Discussion](#)

### PRIMARY TUMOR RISK FACTORS

### ADJUVANT THERAPY TO THE PRIMARY SITE



<sup>d</sup>See Principles of Surgery (VULVA-B).

<sup>h</sup>The management of positive margins for HSIL (non-invasive disease) should be individualized.

<sup>l</sup>See Principles of Radiation Therapy (VULVA-C).

Other primary risk factors include: lymphovascular invasion, negative but close tumor margins (<8 mm), tumor size, depth of invasion, and pattern of invasion (spray or diffuse). Nodal involvement (as an indicator of lymphovascular space invasion) may also impact selection of adjuvant therapy to the primary site.

Note: All recommendations are category 2A unless otherwise indicated.

Clinical Trials: NCCN believes that the best management of any patient with cancer is in a clinical trial. Participation in clinical trials is especially encouraged.

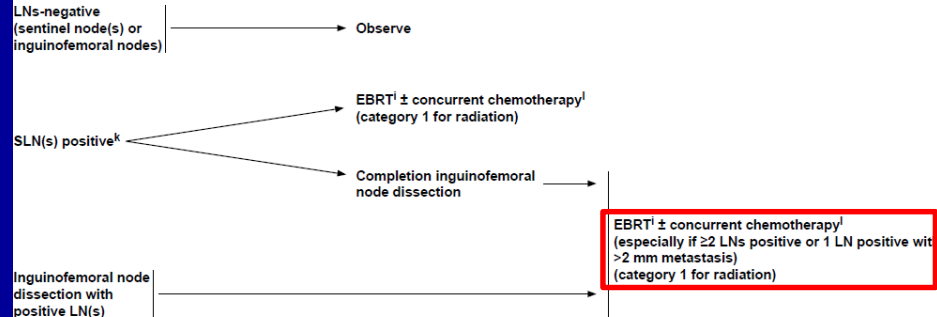
See Surveillance (VULVA-S)  
VULVA-3

NCCN National Comprehensive Cancer Network\*  
NCCN Guidelines Version 1.2017  
Vulvar Cancer (Squamous Cell Carcinoma)

[NCCN Guidelines Index](#)  
[Table of Contents](#)  
[Discussion](#)

### NODAL EVALUATION

### ADJUVANT THERAPY TO THE NODES



<sup>k</sup>See Principles of Radiation Therapy (VULVA-C).

<sup>l</sup>See Principles of Surgery: Inguino-femoral Sentinel Lymph Node Procedure (VULVA-B 3 of 4).

<sup>m</sup>See Systemic Therapy (VULVA-D).

Note: All recommendations are category 2A unless otherwise indicated.

Clinical Trials: NCCN believes that the best management of any patient with cancer is in a clinical trial. Participation in clinical trials is especially encouraged.

See Surveillance (VULVA-S)

# Primary radiotherapy of vulvar cancer

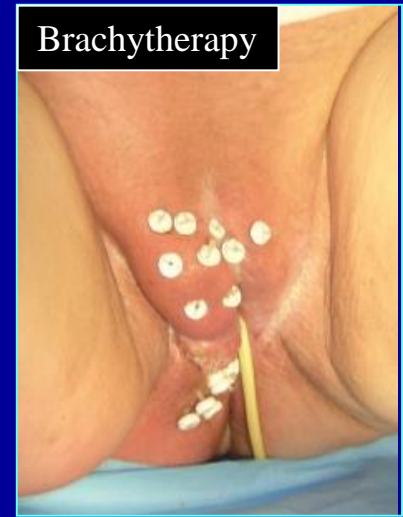Radiochemotherapy – only for young pts. In good general condition!

Phase II clinical studies:

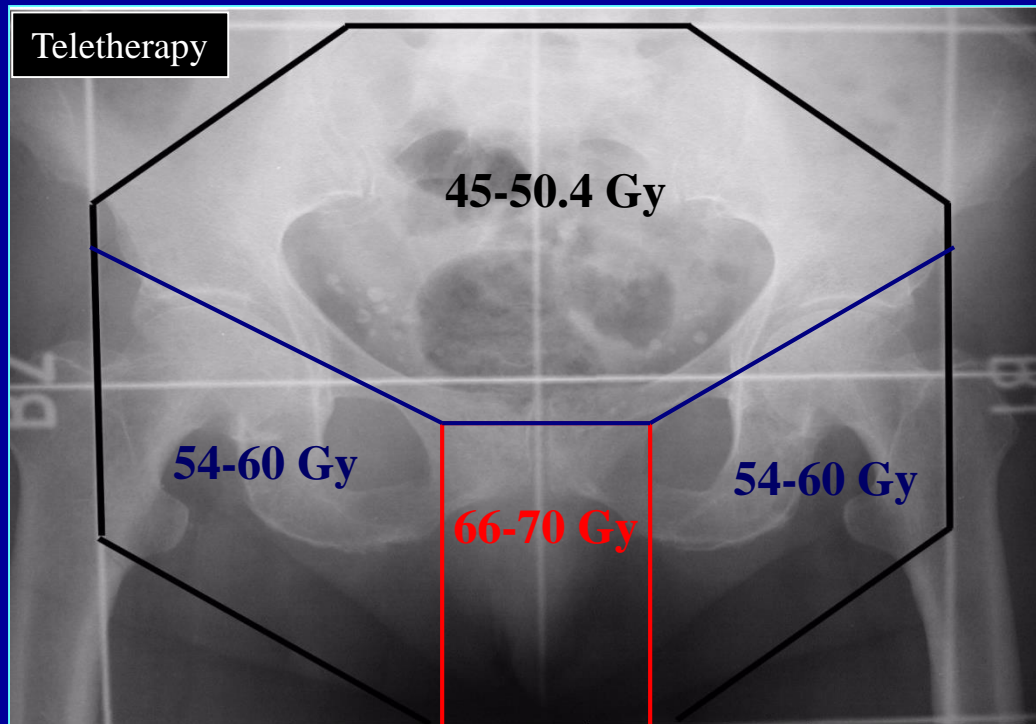
Cisplatin-5-FU – CR: 33-89%

5-FU-Mitomycin C – CR: 42-100%

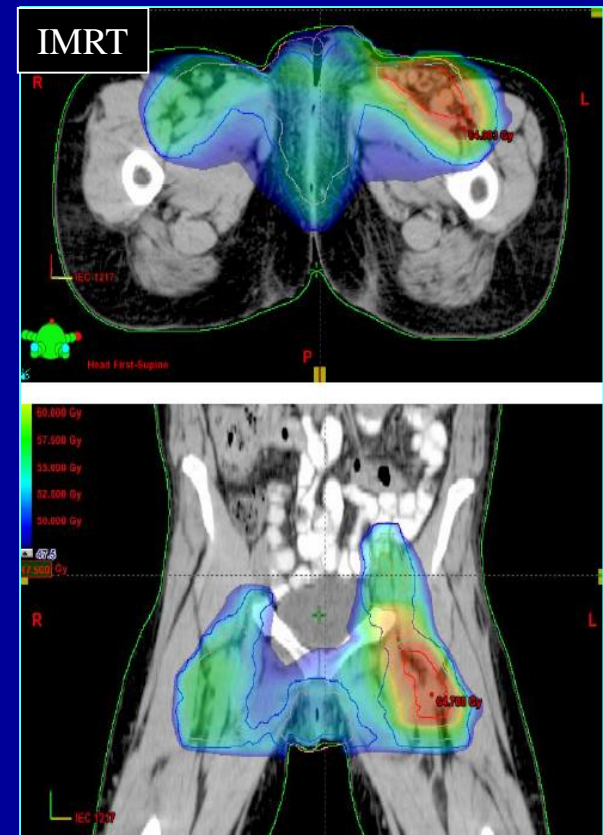
Brachytherapy



Teletherapy



IMRT



# Staging of vaginal cancer




## Symptoms, diagnosis, and staging

### Symptoms:

- Vaginal discharge, bleeding

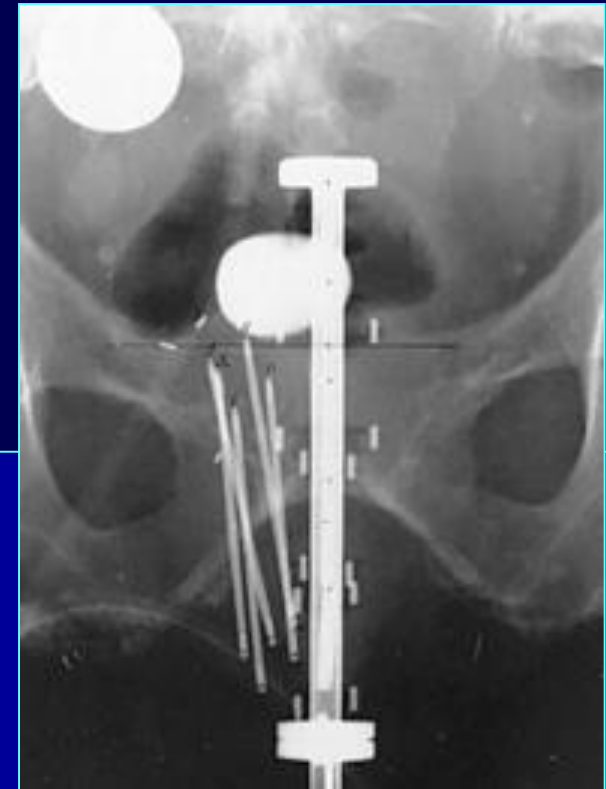
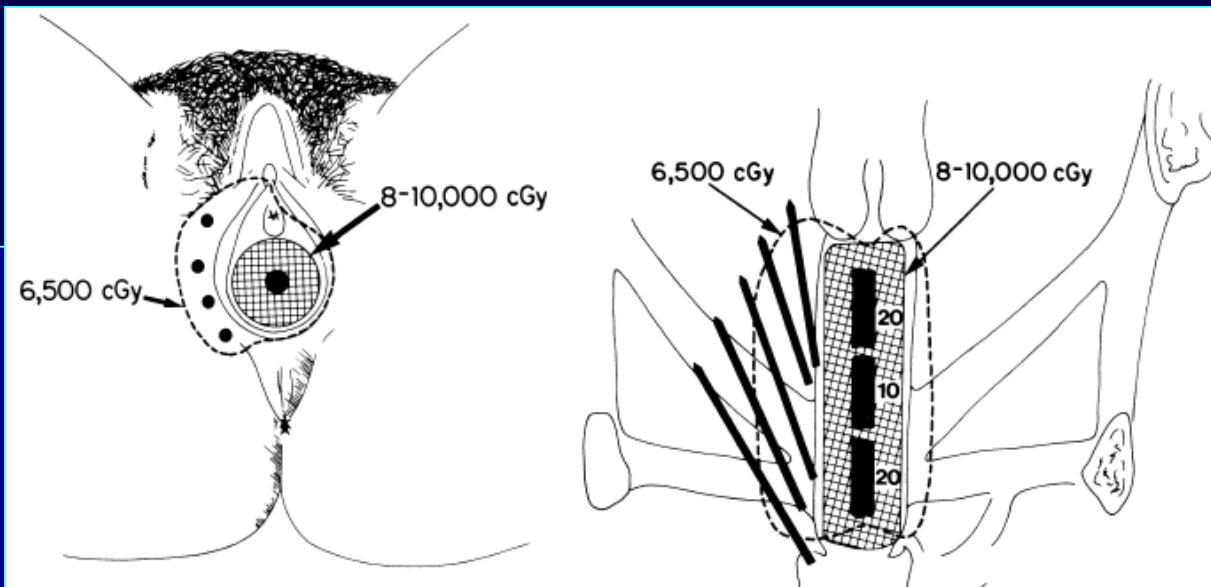
### Diagnostic work-up & staging:

- Physical exam. (inguinal LNs + rectovaginal exam.)
- Inguinal US
- Pelvic CT/MRI
- Incisional biopsy  Szövettan

TNM	FIGO	
Tis	0	In situ cc.
T1	I	Tumour limited to the vagina
T2	II	Paracolpium invaded
T3	III	Paracolpium invaded, pelvic wall
T4	IVA	Bladder/Rectal involvement
N0		No LN met.
N1	III	Regional LN met. (inguinal, pelvic)
M0		No distant met.
M1	IVB	Distant met.

# Radiotherapy of vaginal cancer

- Usually primary RT – good results + function preservation!
  - St. I: BT alone – 5-6 x 7 Gy
  - St. II-IV/A: 45-50.4 Gy external beam RT + 3-5 x 7 Gy BT
  - Local control: St I: 77-88%; St II: 58-68%; St III: 40-60%; St. IV/A: 20-30%
  - Simultaneous radiochemotherapy – limited evidence:
    - Squamous cell. cc: 5-FU-MMC, cisplatin
    - Adenocc + clear-cell cc: 5-FU-VBL



## Palliative RT of GYN tumours

- Individualized treatment according to the volume of the disease and the general condition of the patient
- Lower total dose: 20-50 Gy
- Hypofractionated short RT courses: 10 x 3 Gy, 5 x 4 Gy
- Less sophisticated techniques: two opposed fields
- Vaginal bleeding – 1-2 x 8-10 Gy HDR brachytherapy
- RT of distant metastases:
  - Distant LN mets. (PAO, supraclavicular)
  - Hematogene mets. (bone, brain)





Thank you for your kind attention!

